Sri Lanka Dental Journal

Volume : 43
Number : 03
December : 2013

The Official Publication of the Sri Lanka Dental Association

ISSN 1391-07280

DENTAL SERVICES CO. (PRIVATE) LTD.,

No: 141, Vauxhall Street,
Colombo 02.
Telephone: 0112 421 969, 0112 304 185
Fax No: 0112 304 186

No: 500, Duplication Road,
Colombo 03.
Telephone: 0112 588 005, 0112 501 968

Services Provided:

- Porcelain crown & bridge work
- Orthodontics / Lingual Arch bar, trans palatal arch
- Removable Orthodontic Appliances
- Post crowns & Jacket crowns
- Metal crowns in precious metal, semi precious metal
- Bridge work
- Maryland Bridges
- Chrome cobalt full and partial dentures
- Over denture abutments for Dental Implants

For further details and the price list, please email: **ayesha.familydental@gmail.com**

SRI LANKA DENTAL ASSOCIATION
Professional Center
275/75, Prof. Stanley Wijesundara Mawatha,
Off Bauddhaloka Mawatha,
Colombo 07, Sri Lanka.
Tel/Fax 0094 11 2595147

SRI LANKA DENTAL ASSOCIATION

Sri Lanka Dental Journal

Volume 43 **Number 03** **December 2013**

The **Sri Lanka Dental Journal** is a refereed journal published three times a year by the Sri Lanka Dental Association in collaboration with the College of Dentistry and Stomatology of Sri Lanka, College of General Dental Practitioners of Sri Lanka and the College of Community Dentistry of Sri Lnka.

Editorial Office

Office of the SLDA,
Professional Centre,
275/75, Bauddhaloka Mawatha,
Colombo - 7.

Correspondence regarding editorial matters, articles, reviews and news items should be addressed to the Editor, SLDJ, Prof. Sunethra Rajapakse, Dept. of Oral Medicine & Periodontology, Faculty of Dental Sciences, University of Peradeniya, Sri Lanka.
Tele: 0812 397 552 / 0714 488 800

Correspondence regarding advertisements and financial matters should be addressed to Dr. Malcolm Stanislaus, 50, Hekitta Cross Road, Hendala, Wattala.
Tele: 011 - 2930368

ISSN 1391 - 07280
© SRI LANKA DENTAL ASSOCIATION

Typeset & Printed by:

AK 2 PRO - Udahamulla, Nugegoda.
Tel/Fax : 011 - 2836190

CONTENTS

Sri Lanka Dental Journal 2013; 43(03) 107-108

Sri Lanka Dental Journal

Volume 43 **Number 03** **December 2013**

Editor
Sunethra Rajapakse

Assistant Editors
Udaya Usgodarachchi
Dilum Perera
Hilary Cooray
Ruwan Jayasinghe

Finance Manager
Malcolm Stanislaus

Editorial Board
N.A. de S. Amaratunga
R.L. Wijeyeweera
M.S.Chandrasekara
Lilani Ekanayake
Ajith W. Ranasinghe
Deepthi Nanayakkara
M.A.M. Sitheeque

International Advisers
K.A.A.S. Warnakulasuriya (United Kingdom)
L.P. Samaranayake (Australia)
D.Y.D. Samarawickrama (United Kingdom)
Micheal Mars (United Kingdom)
David Davis (United Kingdom)
Brian Millar (United Kingdom)

Statistical Adviser
Ranjith W. Pallegama

INVITED EDITORIAL

What's really new in orthodontics?

Can something be new in orthodontics? Clinical orthodontics have evolved significantly over the last two decades. During my orthodontic residency, one of my professors told me that 'if you are ever being toldthat there is something new in orthodontics, you should look a little deeper into the orthodontic literature from the past 50 to100 years. It is almost impossible to develop anything new, when it comes to orthodontic biomechanics. To be truly innovative it has to be based on the recent advances made in our understanding of the biology of orthodontic tooth movement and development of new materialsas well as the technologies that were unknown in the past.

Enhanced diagnosis

Diagnostic imaging including panoramic and cephalometric radiographs has been part of the orthodontic diagnostic records for decades. Limitations of the above two-dimensional imaging modalities are superimposition of structures, geometric distortion and magnification. In contrast, Three-dimensional imaging of the skull, jaw and dentition provides a much clear picture of the teeth and other structures. Over the past decade, cone-beam computed tomography (CBCT) has become an important tool to acquire 3-D volumetric imaging to enhance the diagnosis and treatment planning of orthodontic patients. Software that manipulate and view these images from different angles is a powerful means in treatment planning and evaluation of ectopic teeth, pharyngeal airway, the temporomandibular joints and dentofacial anomalies.

The digital era in orthodontics is moving at a rapid pace, by bringing togethernew technologies designed to improve patient care, increase practice efficiency, and save money. Digital intra-oral scanning systems which replacealginate and PVS impressions offer orthodontists more control and accurate impressions, while providing patients with a more acceptable experience and the opportunity for a real-time education about their diagnosis and treatment. By combining intra-oral scanning, CAD-CAM design and the 3-D printing, orthodontists can accurately and rapidly produce study models, clear aligners, indirect-bonding trays and laboratory appliances.

Integration with Other technologies

CBCT and digital imaging and communications in medicine (DICOM) files can now be merged with standard triangulation language (STL) files from digital intra-oral scans to create 3-D renderings of the crowns, roots and bone. Now orthodontists can accurately visualize root positions during different stages of orthodontic treatment by scanning the teeth, rather than taking multiple CT scans that would expose the patient to higher doses of radiation[1]. CBCT and STL scanning files can also be merged to facilitate virtual treatment planning of orthognathic surgical cases, fabrication of surgical guides, placement of temporary anchorage devices, and surgical exposure of ectopic teeth[2].

Clinical and experimental methods to accelerate orthodontic tooth movement

Currently the average orthodontic treatment duration is 2 years with a significant variation which is influenced by factors such as case severity, extraction versus non-extraction, clinical expertise and patient cooperation.In addition to esthetic concerns, time-dependent adverse effects of orthodontic treatment includes root resorption, white spot lesions, dental caries and decreased compliance. Consequently, reduced treatment duration is beneficial to orthodontists and orthodontic patients. Adjunct to appropriate selection of brackets and arch wires, force levels and anchorage planning, a number novel therapies has been introduced to accelerate orthodontic tooth movement.

Direct injury to the alveolar or basal bones of the maxilla and mandible accelerates orthodontic tooth movement by inducing regional acceleratory phenomena (RAP), which is the basis for clinical procedures such as corticotomy-assisted orthodontics, piezocision-aided orthodontics, and surgery-first orthodontics. Nonsurgical methods, such as various physical (resonance vibration, low-energy laser radiation, magnetic fields and electric current) andpharmacologic approaches, also enhance bone remodeling and facilitate tooth movement, and have been shown to be effective in animal and human experiments[3].

Like all medical technologies, the tools and adjuncts for modern orthodontic mechanotherapy are constantly changing. Technology is imperative but should never be substituted for a proper and thorough diagnosis, treatment planning and informed consent.

Sundaralingam Prem Premaraj
BDS, MS, PhD, FRCD (C), FICD
Diplomate of the American Board of Orthodontics
William E. Ludwick Associate Professor and Director of Advanced Specialty Education Program in Orthodontics
University of Nebraska Medical Center College of Dentistry
4000 East Campus Loop South, Lincoln, NE 68583, USA, spremaraj@unmc.edu

References:

1. Lee, R.J., et al., Monitoring of typodont root movement via crown superimposition of single cone-beam computed tomography and consecutive intraoral scans. Am J Orthod Dentofacial Orthop, 2014. 145(3): p. 399-409.

2. Kravitz, N.D., et al., Intraoral digital scanners. J Clin Orthod, 2014. 48(6): p. 337-47.

3. Huang, H., R.C. Williams, and S. Kyrkanides, Accelerated orthodontic tooth movement: molecular mechanisms. Am J Orthod Dentofacial Orthop, 2014. 146(5): p. 620-32.

Review Article

Sri Lanka Dental Journal 2013; 43(03) 109-115

Imaging modalities for dental Implant planning

Jayasinghe Ruwan Duminda

Abstract

Tooth loss is a traumatic and even devastating event so throughout the history mankind tries to find a way to replace missing teeth. Today, dental implants are very popular as a method of replacement of missing teeth as it gives excellent aesthetic as well as functional results. To achieve this, diagnostic imaging plays a vital role. High degree of precision is needed in implant placement. It is important to identify jaw size and shape, available amount and quality of bone and vital structures such as inferior alveolar neurovascular canal and maxillary antrum before placement of implants. Many radiological methods including intra oral radiographs, panoramic radiographs, linear and spiral tomography, spiral and cone beam computed tomography and magnetic resonance imaging are available to assess the bone prior to implant placement. Anatomical considerations for each implant site may allow the clinician to determine the best implant site and best prosthetic outcome. Radiographs are used to evaluate the bone support at the recipient site of the implant at treatment; evaluation and maintenance phases of implant treatment. Several computer software systems are available to analyze the CT data to aid treatment planning and produce physical surgical drilling guidance templates. These templates are computer manufactured and identically match the location, angulation and depth of the planned implant.Eventhough there are many types of imaging modalities are available, the final selection of the imaging modality depends on the patients need and the choice of the operator.

Introduction

Tooth loss is a traumatic and even devastating event so throughout the history mankind tries to find a way to replace missing teeth. Earliest reference to dental implant in modern literature is found in a French work published in 1809[1]. Swedish physician named Per-Ingvar Branemark in 1950s did the major discovery, which was acutely an accidental finding, in relation to dental implants. Prof Per-Ingvar Branemark performed the first clinical case of dental implant placement in 1965 in a mandible of a 34-year-old male. In 1982, Prof George Zarb, a professor of dentistry from University of Toronto who underwent training under Branemark organized the Toronto conference on ossiointergration in clinical dentistry. Popularity of dental implants was increased and many clinicians and researchers accepted the concept of osseintergration and dental implants after this conference[1,2]. Today, dental implants are very popular as a method of replacement of missing teeth as it gives excellent aesthetic as well as functional results. A high degree of precision is needed in implant placement in mandible as well as in maxilla. It is important to identify jaw size and shape, available amount and quality of bone and vital structures such as inferior alveolar neurovascular canal and maxillary antrum before placement of implants.

Dr. Jayasinghe Ruwan Duminda Department of Oral Medicine and Periodontology, Faculty of Dental Sciences, University of Peradeniya, Sri Lanka.

Before the introduction of root form implants, three basic types of implants were available namely subperiostial, blade type and transosseous. Root form implants are widely used today. It has two basic parts, fixture and abutment. Fixture is the part of the implant placed in the bone. It is made of titanium and has various shapes and surface characteristics depending on the manufacturer. Size of the implant will depend on the amount of available bone. Abutment is the part, which increases the height of the fixture above gingival level. It is attached to the fixture by an abutment screw. Dental prosthesis will attach to the abutment.

Multiple types of imaging modalities are available to study the bone prior to implant placement. Until recently, most of the operators were relied on the two dimensional imaging methods whereas in the recent past, three dimensional methods became popular. Some of these techniques such as Computed Tomography (CT) uses a very high dose of radiation but gives a high quality, three dimensional images. In selecting the suitable imaging modality, the operator must consider the diagnostic benefit as well the involved radiation risk. This will allow operator to follow the recommended radiation protection principle of as-low-as- reasonably achievable (ALARA) by the International Commission on Radiological Protection (ICRP).

Many radiological methods are available to assess the bone prior to implant placement and includes intra oral radiographs like IOPA and occlusal, panoramic radiography, cephalometery, Magnetic Resonance Imaging (MRI), conventional tomography and computed tomography. Anatomical considerations for each implant site may allow the clinician to determine the best implant site and best prosthetic outcome. These anatomical goals include (1) determine bone height and width (bone dimensions) (2) determine bone quality (3) determine long axis of alveolar bone (4) identify and localize internal anatomy (5) determine jaw boundaries (6) pathology detection and (7) transfer of radiographic information[3].

Radiographs are used to evaluate the bone support at the recipient site of the implant at treatment; evaluation and maintenance phases of implant treatment. The first phase is the pre-surgical assessment of implant site during treatment planning. Second phase is the pre and intra surgical assessment of surrounding anatomy including measurements from vital structures. Final and third phase is the longitudinal assessment of bone loss around the implant which indicate the success or failure of implant therapy. In this article, we hope to discuss the available diagnostic imaging techniques for dental implant planning as well as their advantages and disadvantages.

Available Radiographic methods for implant planning

Intraoral radiographs

Intraoral radiographs provide adequate information about the trabecular pattern of bone, residual roots, periodontium, angulation of adjacent teeth and surrounding anatomical structures in implant site. They are inexpensive, easy to take, available everywhere and well tolerated by the patients and provide high-resolution images of implant site. Linear measurements in periapical radiographs are closest to actual measurements in any anatomical site and measurement accuracy is almost the same or may even be better than computed tomography[4]. But they are non reproducible, distortions are possible which is inherent to intraoral radiographs and cross sectional details of the available bone is lacking. Because of its small size, they are not suitable for evaluating large edentulous areas and associated mandibular and maxillary structures.

Cephalometric Radiographs

These radiographs provide information about angulation, thickness, vertical bone height, inter jaw skeletal relationships and the soft

tissue profile hence are useful diagnostic aids in implant planning. They are relatively cheap, readily available and easy to perform. However, they have the disadvantage of limited cross sectional information.

Panoramic radiographs

Panoramic radiographs are the most commonly used radiographs by the dental practioners for implant planning alone or in combination with periapical radiographs[5]. A good panoramic radiograph will provide adequate information about bony outline and pathology associated with jaws. Panoramic radiographs provide information for preoperative evaluation as well as important for longitudinal postoperative assessment. It will provide information about the relationship of anatomical structures such as inferior alveolar canal, maxillary antrum and foramina to the implant site. It is relatively cheep and readily available but has a nonuniform horizontal magnification, possibility of position artifacts and lacks cross sectional information. Although it's horizontal magnification is variable due to focus of projection, its vertical magnification is constant and actual magnification will depend on the type of machine used. Angular measurements tend to be accurate, However panoramic radiographs have the greatest measurement deviation to the actual length meaning a risk of loss of measuring precision[4]. Improper patient positioning may further contribute to the image distortion[6]. Predetermination of magnification factor can be accomplished by using a radiographic stent with ball bearings embedded in acrylic and imagined in the patient's mouth. The diameter of ball bearings can be measured radiologically and compared with their actual diameter. Bone measurements then can be adjusted accordingly[6]. For standard implant cases of posterior mandible, panoramic radiography is reliable for clinical use and implant length selection where cross sectional spiral tomography is not compulsory and even can overestimate the vertical bone height[7]. Resolution and shape of panoramic radiograph is less but it gives a broader visualization of jaws and adjoining anatomic structures.

Tomogrpahy

a) Conventional tomography

In conventional tomography, X-ray beam and film move with respect to each other and blurring out the structures that are not in the desired imaging plane. It gives clearer images of structures lying within the plane of interest Conventional tomography is moderately expensive, reproducible, has a uniform magnification and cross sectional images can be taken at any location. Even though there is a magnification, it is uniform hence *correction to it* can easily be made. However, they are not freely available; time consuming than normal panoramic radiography and need considerable experience to interpret the images[8]. Several types of panoramic machines have the linear tomographic option. Different type of motion of the X-ray tube and film are available and include linear, circular, trispiral, elliptical and hypocycloidal[6]. The radiation dose involved in conventional tomography is less than that of the CT. If the whole maxilla or mandible is scanned with cross sectional images, the dose involved in conventional tomography is about 80% of that of CT whereas for edentulous region for 1 to 3 teeth, it is smaller than that of CT[9]. Conventional cross sectional tomographic methods are adequate where replacement of a single tooth or several teeth within a limited area is expected and no significant anatomical variations exist[6]. Taking measurements with conventional tomography is not easy and after studying 4 different panoramic X-ray machines with cross sectional tomographic option, Peltola and Mattila in 2004[10] reported that the intra and inter-examiner variations can be large but can be improved by taking several measurements to take the mean.

(b) Linear Tomography (LT)

In LT Thickness of the image layer depends on

the angle of rotation of the X-ray tube (if the angle is small, image layer is relatively thick). Adjustment of the angle of the objective plane to the angulation of each designed implant site can be obtained easily with the LT by tilting the occlusal plate with the accessory tool. The measurement accuracy of LT is adequate for clinical use as it is less than 1mm[11]. The main disadvantage of LT is the blurring of objects outside the focal plane causing "streak artifacts". In a study done by Butterfield et al in 1997[12] using 5 mandibles and seven experienced subjects, statistically significant inter-observer variability, intra-observer variability and differences between identified and actual anatomical sites of assessed sites were observed. They concluded that these findings demonstrate inherent dimensional instability of LT hence diagnostic and clinical role of LT in assessment of implant site is limited[12]. Most artifacts in LT can be avoided by using a complex motion tomography.

(b) Spiral Tomography (ST)

ST utilizes a spiral type of movements of scanning arm in relation to object and dental film hence produces less image blurring, less distortion and magnification errors when compared to LT. It is diagnostically superior to LT as it can reduce the streak artifacts and blurred images. Some means of relating the cross sectional imaging to the conventional panoramic tomographic images or actual implant site in patients' mouth are necessary. This can be done by the use of surgical stents containing metallic markers, balls, rods or radio-opaque tooth contours. ST can provide valuable information in implant planning especially in cases with minimal crestal width and high aesthetic demands or where exact implant placement is critical for successful treatment outcome[13].

Computed Tomography (CT)

CT is an advanced imaging technique where images are acquired digitally and thereafter formatted into any plane- axial, sagittal and coronal. Spiral movements of the radiation source and image receptors allow capture of information in CT imaging. Several CT software programmes dedicated for oral and maxillofacial use allow mandible and maxilla to be viewed in all three (axial, cross sectional and panoramic) planes. Using identical reformatting algorithm, it is possible to make cross sectional cuts either perpendicular or parallel to dental arch. This type of data reconstruction is called as Multi planner reconstruction (CT/MPR). It is used widely for pre-operative implant planning as it gives a comprehensive assessment of morphology and measurements for dental implants[14,15]. CT has the advantages of uniform magnification, high contrast images, easier identification of bone grafts than conventional tomography, images in three planes, three-dimensional reconstruction, simultaneous study of multiple implant sites and availability of software for image analysis and surgical guidance. Disadvantages of CT include limited availability especially of dental reconstructive software, high cost, high dose of radiation, and lack of usefulness for postoperative follow up due to metallic artifacts. CT techniques and lack of understanding of dentist's need by the radiographer cause higher radiation exposure to the patient than dental panoramic radiography[16]. Radiation exposure and surface absorbed dose to certain critical structures of the maxillofacial region is less in spiral CT when compared to conventional computed tomography[17]. Several computer software systems are available to analyze the CT data to aid treatment planning and produce physical surgical drilling guidance templates. These templates are computer manufactured and identically match the location, angulation and depth of the planned implant.

Cone Beam Computed Tomography (CBCT)

CBCT is a novel development in CT imaging and considered as the state of art technology in dental and maxillofacial imaging. This technique not only reduces the size and cost of CT scanners but also improves resolution of the image with

less radiation dose than that used in CT scans. Images can be acquired within seconds.

CBCT, also known as volumetric CT (VCT) uses a cone shaped beam of X-ray photons where as conventional spiral CT uses a fan shape beam. A single 360° rotation of tube detector system is sufficient in CBCT to scan the region of interest in contrast to the multiple rotations required by spiral CT. This rotation produces the initial data or raw data, which are presented as a lateral tomogram. The raw data are used for primary reconstruction. The options for the thickness of the layers to be reconstructed are in the range of 0.12mm to 3mm and reconstruction angles can be determined by the clinician. The primary images can be used for further secondary reconstructions in all planes and for three-dimensional reconstructions[18,19]. As the volume of interrogates is much smaller in CBCT, it is also referred to as 'micro CT'[19]. CBCT has better spatial resolution on cross sectional images than spiral CT. Image quality is as good as conventional CT and it has a voxel (the smallest detectable unit) size which may be as low as 0.12mm (it is 0.5- 1mm in most spiral CT units)[20]. Due to this isotropic sub millimeter spatial resolution, its use is suited well for dental and maxillofacial cases.

CBCT can acquire rapid volumetric images in a shorter time and with a very low radiation risk to the patient, the amount of radiation exposure can be similar to that of a full mouth series. CBCT provides excellent information about cortical integrity and thickness, bone marrow spaces, post extraction irregularities and trabecular bone density[21]. Software in the CBCT allows multiplanar reformation and display. Primary reconstruction of raw data takes place parallel to the occlusal plane and reconstruction can occur in axial, coronal, saggital, curved and oblique planes[3]. CBCT based dental imaging can be used for both implant planning and surgical guidance[22]. Although CBCT images can underestimate the real distance between various skull sites, these differences are only significant for the skull base hence CBCT linear measurements at other sites are reliable and can be used for clinical evaluation[23].

Magnetic Resonance Imaging (MRI)

MRI, especially the low field scanner has shown some good potential for future use in implant planning. It can produce clear images in which implant sites can be identified easily in relation to template. It has the advantage over CT, as it does not use any ionizing radiation. Artifact production is low, localized and confound around ferromagnetic structures such as steel dentinal pins[24]. This is a big advantage over CT where artifacts are common around dental amalgam filling with loss of image quality. Total flexibility of slice alignment is possible with MRI and does not need reformatting. Although the cost of low-filed scanner is very much higher than the CT, its availability and cost may come down in future. As it is different from CT, considerable experience is needed for interpretation of MRI images. The major advantage of the MRI is the negligible radiation risk because no ionizing radiation is used.

Computer assisted implant planning

Introduced in 1993, SimPlant software combines CT imaging with computer-aided design. Earlier, before the introduction of this software, implant treatment planning was based on hard copies of images or copies of reformatted images. Transparent implant overlays were used to plan implant placement. SimPlant uses the raw data from CT imaging together with computer graphics and provide impressive tool to plan implant placement. SimPlant provides a varying set of reformatted CT images in relation to bony anatomy of the alveolar ridge. Bony height and width as well as bone density can be measured easily[6]. The software allows the clear visualization of inferior alveolar nerve with a safe margin and other structures, therefore, allowing simulated implant planning. It is possible to select the correct length as well as

the diameter of implant and correct abutment for implant. Any type of implant can be selected from the provided implant library. Angulations of the implant can be changed and modified on the screen for optimal orientation. It is possible to plan the maxillary sinus graft using SimPlant. It will allow the operator to plan the required amount of bone before the surgery.

Several different software packages have been developed and are available for both CT (SURRLAN) and reformatted CT (Denta Scan, SimPlant). These programs give an interactive platform allowing analysis of potential implant sites for bone quality quantity and morphology.

Summary

A comprehensive radiological assessment together with clinical examination can only provide the necessary information to select optimal site, size and number of implants to be placed. The selection of technique of radiological investigation should be based on weighing the required image quality against radiation risk and cost involved. As the conventional radiographs do not provide adequate radiological information, cross sectional imaging is advisable for most cases, especially in cases of complex reconstruction. Imaging modalities with higher radiation risk like CT has to be limited for the difficult or multiple implant cases.

Even tough there are many types of techniques and recommendations are available, final decision of the technique to be used in implant planning has to be taken by the clinician taking all variables into consideration.

References

1. Sullivan RM. Implant dentistry and the concept of osseointergration: A historical perspective. CDAJ 2001; 29: 737- 45

2. Alberktsson T and Wennerberg A. The impact of oral implants- past and future, 1966- 2042. J Can Dent Asso 2005; 71: 327

3. Hatcher DC, Dial C and Mayorga C. Cone beam CT for pre-surgical assessment of implant sites. Cal Dent Asso J 2003; 31: 825- 33

4. Wahoh M, Harada T, Otonari T et al. Reliability of linear distance measurement for dental implant length with standardized periapical radiographs. Bull Tokyo Dent Coll 2006; 47(3): 105- 115

5. Sakakura CE, Moris JAND, Lofferedo LCM and Scaf G. A survey of radiographic prescription in dental implant assessment. Dentomaxillofac Radiol 2003; 32: 397- 400

6. Mupparapu M and Singer SR. Implant Imaging for dentist. J Canadian Dent Asso 2004; 70: 32- 32g

7. Frei C, Buser D and Dula K. Study on the necessity for cross section imaging of the posterior mandible for treatment planning of standard cases in implant dentistry. Clin Oral Impl Res 2004; 15: 490-7

8. Tyndall DA and Brooks SL. Selection criteria for dental implant site imaging: A position paper of the American Academy of Oral and Maxillofacial Radiology. Oral Surg Oral Med Oral Pathol Oral Radiol Endod 2000; 89: 630-7

9. Dula K, Mini R, van der Stelt PF and Buser D. The radiographic assessment of implant patients: decision making criteria. Int J Oral Maxillofac Implants. 2001; 16 (1): 80-9

10. Peltola JS and Mattila M. Cross-sectional tomograms obtained with four panoramic radiographic units in the assessment of implant site measurements. Dentomaxillofac Radiol 2004; 33:295- 300

11. Naitoh M, Kawamata, A, Iida H and Ariji H. Cross-Sectional Imaging of the Jaws for Dental Implant Treatment: Accuracy of Linear Tomography Using a Panoramic Machine in Comparison with Reformatted Computed Tomography. Int J Oral Maxillofac Implants 2002;17:107-112

12. Butterfield KJ, Dagenais M and Clokie C. Linear tomography's clinical accuracy and validity for presurgical dental implant analysis Oral Surg Oral Med Oral Pathol Oral Radiol Endod 1997;84:203-9

13. Dixon DR, Morgan R, Hollender LG, Roberts FA and O'Neal RB. Clinical application of spiral tomography in anterior implant placement: Case report. J Periodontol 2002; 73: 1202-9

14. Schwarz MC, Rothman SLG, Rhodes ML and Chafetz N. Computed tomography: Part I. Preoperative Assessment of the mandible for endosseous implant surgery. Int J Oral Maxillofac Implants 1987; 2: 137-41

15. Schwarz MC, Rothman SLG, Rhodes ML and Chafetz N. Computed tomography: Part II. Preoperative Assessment of the maxilla for endosseous implant surgery. Int J Oral Maxillofac Implants 1987; 2: 143-48

16. Lecomber AR, Yoneyama Y, Levelock DJ, Hosoi T and Adams AM. Comparison of patient dose from imaging protocols for dental omplant planning using conventional radiography and computed tomography. Dentomaxillofac radiol 2001; 30: 255-9

17. Bianchi J, Goggins W and Rudolph M. In vivo thyroid and lens surface exposure with spiral and conventional computed tomography in dental implant radiography. Oral Surg Oral Med Oral Pathol Oral Radiol Endodon 2000; 90: 249-53

18. Tsiklakis K, Syriopoulos K and Stamataki HC. Radiographic examination of the temperomandibular joint using cone beam computed tomography. Dentomaxillofac Radiol 2004; 33: 196-201

19. MacDonald-Jankowski DS and Orpe EC. Computed tomography for oral and maxillofacial surgeons. Part 2: Cone-beam Computed tomography. Asian J Oral Maxillofac Surg 2006; 18: 85-92

20. Pinsky HM, Dyda S, Pinsky RW, Misch KA and Sarment DP. Accuracy of three-dimensional measurement using cone-beam CT. Dentomaxillofac Radiol 2006; 35: 410-6

21. Guerrero ME, Jacobs R, Loubele M, Schutyser F, Suetens P and Steenberghe D. State-of-the-art on cone beam CT imaging for preoperative planning of implant placement. Clin Oral Invest 2006; 10: 1-7

22. Almog DM, LaMar J, LaMar F and LaMar F. Cone beam computerized tomography based dental imaging for implant planning and surgical guidance, part I: single implant in the mandibular molar region. J Oral Implantol 2006; 32: 77-81

23. Lascala CA, Panella J and Marques MM. Analysis of the accuracy of linear measurements obtained by cone beam computed tomography (CBCT-NewTom). Dentomaxillofac Radiol 2004; 33:291- 294

24. Gray CF, Redpath TW and Smith FW. Low field magnetic resonance imaging for implant dentistry. Dentomaxillofac Raiol 1998; 27: 225-29

Research Article

Sri Lanka Dental Journal 2013; 43(03) 116-125

Factors related to dental injuries and determining the category of hurt: a medico-legal analysis

M. Vidanapathirana

Abstract

Introduction: Dental injuries have not been studied in detail from a medico-legal point of view. This study was conducted to describe the types, circumstances, associations and determining upon category of hurt in dental injuries.

Methods: A cross-sectional study was conducted at a tertiary care hospital from January 2009 to December 2013. Medico-Legal Examination Forms (12,095) were perused and there were 153 cases with dental injuries. Of them, 147 cases in which the dental injuries were the determinant factor for categorization of hurt were considered in this study.

Results: Fifty eight percent reported following Road traffic trauma (RTT) and remaining 42% were assaults. Fifty seven percent had fractures, 08% had dental dislocations and 29% had subluxations. Seventy seven percent were grievous hurt. Out of 43 traumatic subluxations, 17 had not returned for dental review. None of the intra-oral X-rays carried identification number. Those were categorized as non-grievous due to non-compliance. Fractures/dislocations were common among males (p=0.028), below 30 years (p=0.000) and in RTT victims (p=0.000).

Conclusions: More severe dental fractures/ dislocations were common among males, RTT victims and below 30 years persons. In traumatic subluxation, dental experts should emphasis the importance of 'review dental medico-legal examination after 20 days' to enhance victim compliance and to achieve categorization of hurt. To ensure authenticity, include identification number in all medico-legal X-rays. It is necessary to enforce existing laws of motor traffic and criminal behaviours to minimize dental injuries. The development of evidence based preventive program and medico-legal management guidelines for dental injuries are suggested.

Keywords: Dental injuries, categorization of hurt, Sri Lanka (Word count 250)

Introduction

Patients with dental injuries are examined by forensic medical practitioners on Medico-legal examination forms (MLEFs) issued by police. Some patients directly present to forensic medical practitioners with MLEFs obtained by police and other patients get admitted to hospital and referred to forensic medical practitioners with MLEFs issued by police for medico-legal examination.

When dental injuries are presented to forensic medical practitioners, they seek expert opinion of dental surgeons. Those expert opinions on dental injuries are used in criminal and civil investigations to ascertain the category of hurt, identification, assessment of age and to

Dr. M. Vidanapathirana (Correspondence) Consultant in Forensic Medicine, Teaching Hospital, Colombo South, Senior Lecturer, Department of Forensic Medicine, Faculty of Medical sciences, University of Sri Jayewardenepura. Tel: +94 77 2988227 Fax: +94 11 2801480 E-mail: mudithavidana@gmail.com

determine compensation etc.

For example, the expert opinion of the dental surgeon on 'mobile teeth' is important to decide between natural and traumatic subluxation. If traumatic subluxation, it should be reviewed after 20 days to ascertain the category of hurt. Formulation of the medico-legal opinion on dental injuries by dental surgeon depends on his or her awareness on the objectives of medico-legal examination. However, this awareness on the part of dental practitioners limited due to non-availability of accepted guidelines or protocols for medico-legal management of dental injuries.

Road traffic accidents and use of lethal weapons etc. cause severe oral and maxillofacial injuries. Though laws exist in Sri Lanka to prevent road traffic accidents and assaults, prevention of dental injuries occurring in such situations are not sufficiently addressed. Some medico-legally significant dental injuries such as domestic dental injuries are not reported. Dental injuries due to child abuse and neglect may be the most vulnerable for non-reporting.

Development of evidence based medico-legal management strategies and preventive measures of dental injuries are important but the dental injuries have not been studied in detail from a medico-legal point of view in Sri Lanka. Therefore, this study was conducted to describe the types, circumstances, associated factors and determination of the category of hurt of dental injuries among the cases reported to forensic medical practitioners for medico-legal purposes.

Methods

A retrospective cross-sectional study was conducted at a tertiary care hospital. All (12,095) Medico-legal examination forms (MLEFs) of five consented forensic medical practitioners covering 5 year period from 1st of January 2009 to 31st of December 2013 were screened and 153 reported dental injuries. Of them, 6 cases were excluded since category of hurt was determined by injuries other than dental injuries. The remaining 147 cases, where the dental injuries were the determinant factor for categorization of hurt were considered in this study.

The clinical findings that are routinely documented by forensic medical practitioners on 'Medical Officer's copy of the MLEFs' were considered in this study. The forensic medical practitioner routinely records the demographic data and details of the incident obtained from the hurt person. Further, details pertaining to injuries are gathered from notes made by medical officers in the bed head ticket. Subsequently, then the forensic medical practitioner's observations, examination findings including dental injuries and investigation findings especially X-ray findings are documented. Further, referrals to relevant specialists including dental surgeons on a special pro-forma and their expert opinions are also documented. Forensic medical practitioner has to review some patients with the reports of dental reviews, especially after 20 days of the incident. Having collected above information, the opinions that forensic medical practitioner arrives include: the type of force used (blunt, sharp or other) and category of hurt (non-grievous, grievous, endangering life or fatal in the ordinary cause of nature). The duly filled 'police copy of the MLEF' is returned to the relevant police station.

The demographic data and the factors related to the incident such as date, time, place, circumstances, details of injuries, investigations, the opinions such as type of force and category of hurt were extracted from the retained 'medical officer's copy of the MLEF', on to a data collection form. Medical reports and police reports were used as secondary sources.

When classifying the incidents according to the area of occurrence, those that had occurred in municipal council areas were considered as

urban and others were considered as rural.

In the current study, for the categorization of hurt of oral or maxillofacial injuries, according to the severity following order was considered: maxillofacial fractures, dislocation of a tooth, fracture of a tooth, subluxation and 'only soft tissue injuries'. In the event where more than one oral or maxillofacial injuries are found, according to the above sequence, the most severe injury was considered for categorization of hurt.

According to the dental surgeon's opinion, Grade II and grade III mobility were considered as subluxated.

For categorical variables, frequencies were calculated. For quantitative variables, mean, median standard deviation or interquartile ratios were calculated. Chi2 test was performed to examine the associations between categorical variables and p-value <0.05 was considered statistically significant. The SPSS version 19 was used in statistical calculations.

Permission for the research was obtained from the ethical clearance committee of the Teaching Hospital Colombo South.

Results

Out of 12,095 Medico-Legal Examination Forms (MLEFs), the proportion of dental injuries was 1.2% (153). Of them, 147 cases, the dental injury was the determinant factor in deciding upon the category of hurt. There were no patients examined on 'court orders'.

Eighty four percent (n=123) were males. Age of the victims ranged from 03-79 years. Most (n=39) were between 20-29 years. The median age was 34 years and interquartile range (IQR) was 23-51 years. Thirty five percent (n=52) were below 30 years of age. Of them, 08% (n=12) were children under the age of 18 years. Of the 12 children with dental injuries, 07 were following Road traffic trauma (RTT) and 05 following assaults including 2 cases due to physical child abuse. Further, in the group less than 30 years of age, 63% (n=33) dental injuries were due to RTT and the remaining 37% (n=19) were due to assaults. The characteristics of the sample are shown in Table 1.

Table 1. Characteristics of the sample (N=147)

Character	Number	Percent
Sex		
Male	123	84.0
Female	24	16.0
Age		
00-29	52	35.0
30-59	81	55.0
=>60	14	10.0

Thirty three percent (n=48) were unemployed and 63% (n=92) were married. According to the ethnicity, 91% (n=134) were Sinhalese, 05% (n=07) Moors, 03% (n=04) Burgers and 01% (n=02) were Tamils.

Regarding the place of incidents, 56% (n=82) occurred in rural areas.

Among the circumstances of dental injuries, 58% (n=85) were following RTT and remaining 42% (n=62) following assaults. There were no reported cases following accidental falls, sports dental injuries, industrial injuries, therapeutic dental injuries and dental malpractices etc. The place of the incident and the circumstances are shown in Table 2.

All cases had associated soft tissue injury. Types of oral and maxillofacial injuries were fractures, dislocations (Figure 1), subluxations (Figure 2) and 'only soft tissue injuries'. Fifty seven percent (n=84) had oral and maxillofacial fractures such as crown (Figure 1), maxillofacial and mandibular fractures. Two root fractures were considered under subluxation. The distribution of injuries is shown in Table 3.

All victims had been referred and examined by dental experts with X-rays but none of the intra-oral dental X-rays carried identification numbers.

When classified according to the 'force applied', all had been subjected to blunt force trauma.

Table 2. Characteristics of the incident (N=147)

Character	Number	Percent
Place of incident		
Rural	82	56.0
Urban	65	44.0
Circumstance		
RTT	85	58.0
Assaults	62	42.0

Table 3. Types of oral and maxillofacial injuries that was taken for the categorization of hurt (N=147)

Type	Number		Percent	
Oral and maxillofacial fractures				
Crown fractures	78	84	53%	57.0
Maxillofacial fractures	04		03.0	
Mandibular fractures	02		01.0	
Dislocations	12		08.0	
Traumatic Subluxations	43		29.0	
Only soft tissue injuries	08		06.0	

According to the categorization of hurt, 77% (n=114) were grievous, 20% (n=29) non-grievous and 03% (n=04) were endangering life. None had 'fatal in the ordinary cause of nature' dental injuries.

There were 29% (n=43) traumatic subluxations. Of them, 08 were not reviewed: 04 were due to application of active dental therapy (wiring or plastering) (Figure 3), 02 extractions and 02 root fractures. Those 08 were categorized as grievous hurt by the forensic medical practitioner without dental review.

59% (n=72) of male victims with dental injuries and 54% (n=13) of female victims and this differences was not significant (p=0.692).

Of dental injuries due to RTT , 62% (n=51) were rural incidents and 52% (n=34) were urban incidents and this difference was not significant (p=0.228).

When types of injuries according to their severity considered 2 groups identified were more severe fracture/dislocation and less severe subluxation/'only soft tissue injuries'.

Figure 1. Traumatic crown fractures and dislocations

Figure 2. Traumatic subluxations

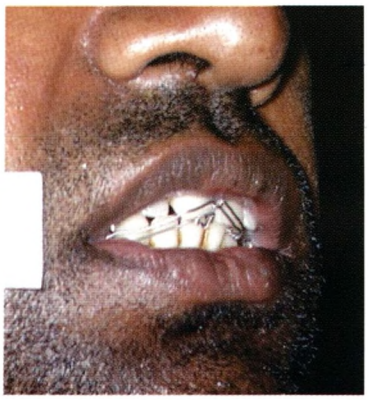

Figure 3. Wiring for traumatic subluxation

The remaining 35 victims with traumatic subluxation were advised to be reviewed by the dental surgeon after 20 days. Of them, 14 were certified as 'mobile' even after 20 days by dental experts and therefore, those were categorized under grievous hurt by forensic medical practitioner. In the 'after 20 days review' 04 were certified as 'fixed' by dental experts and therefore, those were categorized as non-grievous by forensic medical practitioners. The remaining 17 had not turned up for dental review after 20 days and were categorized as non-grievous by the forensic medical practitioner due to non-compliance.

When circumstances under which injury occurred is considered two groups identified were RTT and assaults. RTT was found among,

Fractures/dislocations were found among, 69% (n=85) of males and 46% (n=11) of females and this difference was significant ($\chi2$=4.800, p=0.028<0.05).

Fractures/dislocations occurred among, 82% (n=70) of RTT victims and 42% (n=26) of assaulted victims and this difference was statistically significant ($\chi2$=25.848, p=0.000<0.01).

Fractures / dislocations were found among, 88% (n=46) of below 30 years old group and 53% (n=50) of 30 years and above age group and this difference was statistically significant ($\chi2$=19.041, p=0.000<0.01).

Discussion

To ascertain the category of hurt in dental injuries, dental surgeon's expert opinion is essential. The medical practitioner who practices a field of medicine day to day is considered as an expert and therefore, the dental surgeon is the expert in giving opinion on dental injuries. Based on dental expert opinions, the forensic medical practitioner formulates the medico-legal opinion on such injuries.

In this retrospective study covering 5 year period, majority of dental injuries were grievous hurt and were due to Road traffic trauma (RTT). Severe injuries such as fractures/dislocations of teeth were significantly more following RTT, in males and among younger group age less than 30 years.

This study did not come across any case of 'non-road traffic accidental falls' simply because victims of such dental injuries are not considered of any medico-legal importance and such victims are not issued with MLEFs.

Victims with dental injuries directly report to police or inform to police by the hospital. The injured patients are issued MLEFs by relevant police/ hospital police post and referred to the forensic medical practitioner. Sometimes, patients are brought to the forensic medical practitioner by police on court order. In this study, no patients with dental injuries were brought on court orders.

In this study, out of 12,095 Medico-Legal Examinations, the proportion of traumatic dental injuries was 1.2%. Whereas, in a community study done by Glendor in 2008, 25% of school children and 33% of adults had traumatic dental injuries (1). The lower proportion of traumatic dental injuries in the current medico-legal study may be due to non-reporting of injuries following accidental falls by the victims as well as the clinicians to police.

Similar to studies done by Ugboko and others in 1998 (2), Ramli and others in 2011 (3) Batista and others in 2012 (4), dental trauma were common among males. Dominance of male victims suggests the male dominant society in Sri Lanka.

In this study, the number of victims below 18 years of age was few and were 8% (n=12). According to a study done at a University Dental Hospital in 2008 in Sri Lanka, the most frequent cause for dental trauma in children was 'accidental fall' (89%) (5). The low proportion of child victims in the current study may have been again due to non-reporting of accidental falls for medico-legal examination. However, the presence of two physical child abuse cases encourages further examination to identify real incidence of dental injuries and also highlights the fact that physical child abuse victims with dental injuries needed to be identified by clinicians and referred to forensic medical practitioners for medico-legal examination.

A study done by Al Ahmed and others in 2004 (6), showed that the highest number of dental injuries was for persons within the range of 20 to 29 years. In this study, median age was 34 years and interquartile range (IQR) was 23-51 years and the most number of victims (n=39) belonged to 20-29 years.

Study done by Batista and others in 2012 (4), reported that the oral and maxillofacial trauma were common in urban areas (67.6%), whereas in this study, most incidents had occurred in rural areas (56%). Though, majority (58%) of dental injuries were due to RTT, most RTT incidents (62%) had taken place in rural areas. This needs further investigation.

Dental injuries occur under different circumstances such as assaults, road traffic trauma (RTT), non-road traffic accidental falls, sports injuries, therapeutic dental injuries etc. In this study, only RTT and assaults were reported

for medico-legal examination. Accidental and sports dental injuries are not reported to police as there are no medico-legal significance. Industrial and therapeutic dental injuries or dental malpractices were not reported in this study and it is something we need to make a note of.

Similar to a study done by Batista and others in 2012 (4), in this study too, RTT was the most common cause of oral and maxillofacial fractures/dislocations.

Intrusion beyond 6 mm cannot regenerate a functional periodontal ligament and are prone to root resorption and eventual extraction. In these situations the decision is either immediate extraction or repositioning with the understanding that it is inevitable that the tooth will eventually be extracted (7). When such extractions are done by the dental surgeon for traumatic subluxation, the injury is categorized as grievous by the forensic medical practitioner.

When root fractures are found in traumatic subluxation by the dental surgeon, the injury is categorized as grievous by the forensic medical practitioner (9).

Splinting is the standard of care for stabilization of replanted or repositioned permanent teeth following trauma (8). When such active dental therapy is used in traumatic subluxation, the injury is categorized as grievous hurt (9).

In this study, there were 43 victims with mobile (subluxation) teeth. The phenomenon of a 'mobile tooth' is a medico-legal challenge. In such instances, the dental surgeon's expert opinion is required to ascertain traumatic or natural subluxation. A traumatic subluxation is categorized as grievous hurt under section 311of the penal code of Sri Lanka (9) in following circumstances: (a) root fracture, (b) subluxation that warrants extraction of affected tooth/teeth, (c) active dental therapy such as wiring or plastering, (d) if mobility persists more than 20 days of the incident.

According to the above criteria there were 02 cases of subluxation due to root fracture, 02 cases of mobile tooth needing extraction and 04 cases that needed active dental therapy and those 08 cases were classified as grievous hurt without necessitating further review.

Fixation of a 'mobile tooth' depends on multiple reasons. Review is important to decide whether a mobile (subluxated) tooth has fixed or not after 20 days in order to categorize hurt. If traumatic subluxation persists for more than 20 days it is categorized as grievous hurt and if fixes within 20 days it is non-grievous hurt. Out of 43 mobile teeth, 14 cases were found 'mobile' even after 20 days by dental surgeon and were categorized as grievous hurt by the forensic medical practitioner (9). Four were found 'fixed' after 20 days by dental surgeon and were categorized as non-grievous hurt by forensic medical practitioner.

Seventeen victims out of 43 subluxated cases did not present for the 'review after 20 days' making them to be categorized as non-grievous by the forensic medical practitioner due to non-compliance. This is an important finding since this non-compliance by the patient may have been prevented or reduced by emphasizing the importance of presenting to 'review after 20 days' by the forensic expert examined and/or more so by the dental surgeon concerned.

Crown fractures are categorized as grievous hurt under the penal code of Sri Lanka (9). There were 78 (53%) victims with crown fractures and in the study of Olsburgh and others in 2002 too, the crown fractures accounted for the highest percentage of all traumatic injuries in the permanent dentition (10).

Avulsion or dislocation of teeth is also considered as grievous hurt. In this study, there were 12 (8%) dislocations. According to Kenny

and others in 2003, if replanted within 5 minutes of avulsion, there is a chance of regeneration of the periodontal ligament and normal function (7). However, according to Sri Lankan grievous hurt law, even complete recovery without any complication following dental treatment or cosmetic surgery does not prevent such injuries being classified as grievous hurt.

Maxillofacial fractures (n=04) were categorized as endangering life under the penal code since the force that gives rise to the maxillofacial fracture may have effects on consciousness such as concussion.

In this study, the 2 root fractures were confirmed by peri-apical X-rays by the dental surgeon. X-rays is an important method of documentation and peri-apical dental X-rays are taken to capture the tip of the root. In dental injuries, intra-oral X-rays such as peri-apical, bitewing, palatal and extra-oral X-rays such as orthopantogram are taken. The orthopantograms are medico-legally more useful not only that it shows a panoramic view of the entire dentition and other adjacent structures on a single film but also it carries an identification number and site, which are important for medico-legal purposes. In this study none of the intra-oral dental X-rays carried identification numbers making them not useful to prove authenticity in medico-legal proceedings.

Traumatized teeth present a clinical challenge with regard to their diagnosis. Recent developments in imaging systems have enabled clinicians to visualize structural changes effectively. Computed tomography (CT), magnetic resonance imaging (MRI) and cone beam computed tomography are among the most commonly used systems in some countries (11). Application of such investigations among the victims of this study was not reported.

In this study, it was found that RTT caused more severe injuries such as fractures/dislocations when compared to injuries due to assaults ($p<0.05$). This could have been due to higher force of impact in RTT when compared to assaults.

Further, it was revealed that among males, the chance of getting severe fractures/dislocations were more common when compared with females ($p<0.05$). This could have been due to presence of more males than females in RTT which would yield a higher force and resulting severe injuries.

In this study, it was revealed that the younger victims below 30 years suffered severe injuries such as dislocations/fractures of teeth compared the 30 years or more age group ($p<0.05$). This could have been due to presence of more victims below 30 years (63%, n=33) than 30 years or above (37%, n=19) in RTT which would yield a higher force and resulting severe injuries. Further, this may be due to lesser maturity and strength of young teeth.

In some countries, due to legislative changes and preventive measures involving the use of seat belts, air bags and driving under the influence of alcohol, the vehicle accidents resulting dental injuries have decreased, while interpersonal violence has emerged as the predominant cause (12,13). In Sri Lanka, though there are no special air bag laws, there are laws to regulate the use of seat belts and driving under the influence of alcohol. According to the Motor traffic act of Sri Lanka, 1990, driving after consumption of alcohol or drugs is banned. According to the Motor Traffic (Seat Belts) regulation gazette issued by Transport Ministry in 2011, it is mandatory wearing seat belts by every person travelling in the driving seat or the front passenger seat of motor vehicles specified in the gazette. In spite of the legislative changes in Sri Lanka, RTT turned out to be the predominant cause for dental injuries in this study, necessitating further research.

Conclusions

More severe dental fractures/dislocations were common among males, RTT victims, and persons below 30 years of age. In traumatic subluxations, dental experts should emphasis the importance of 'review medico-legal dental examination after 20 days' in order to enhance victim compliance and to achieve accurate categorization of hurt. Inclusion of an identification number especially in all medico-legal X-rays to ensure the authenticity is reiterated.

To minimize dental injuries, it is necessary to enforce existing laws related to motor traffic and criminal behaviours. Further, the development of evidence based preventive program and the development of evidence based medico-legal management guidelines for dental injuries are suggested.

Acknowledgment

Dr. DSK Karunanayake, Dr. ND Ruchira, Registrars Dr. HKR Sanjeewa, Postgraduate trainees and Dr. H Suffian at the Office of the Judicial Medical Officer, Teaching Hospital, Colombo South for collection of samples.

References

1. Glendor U. Epidemiology of traumatic dental injuries- a 12 year review of the literature. Dental Traumatology 2008; 24(6): 603-11.

2. Ugboko VI, Odusanya SA, Fagade OO Maxillofacial fractures in a semi-urban Nigerian teaching hospital. A review of 442 cases. International Journal of Oral and Maxillofacial Surgery 1998; 27(4): 286-9.

3. Ramli R, Rahman NA, Rahman RA, Hussaini HM, Hamid AL. A retrospective study of oral and maxillofacial injuries in Seremban Hospital, Malaysia. Dental Traumatology 2011; 27(2): 122-6.

4. Batista AM, Marques LS, Batista AE, Falci SG, Ramos-Jorge ML Urban-rural differences in oral and maxillofacial trauma. Brazilian Oral Reseach 2012; 26(2): 132-8.

5. Ekanayake L, Perera M. Pattern of traumatic dental injuries in children attending the University Dental Hospital, Sri Lanka. Dental Traumatology 2008; 24(4): 471-4.

6. Al Ahmed HE, Jaber MA, Abu Fanas SH, Karas M. The pattern of maxillofacial fractures in Sharjah, United Arab Emirates: a review of 230 cases. Oral Surgery, Oral Medicine, Oral Pathology, Oral Radiology and Endodontics 2004; 98(2): 166-70.

7. Kenny DJ, Barrett EJ, Casas MJ. Avulsions and intrusions: the controversial displacement injuries. Journal of Canadian Dental Association 2003 May; 69(5):308-13.

8. Andreasen FM, Andreasen JO, Bayer T. Prognosis of root-fractured permanent incisors--prediction of healing modalities. Endodontic Dental Traumatology 1989; 5(1): 11-22.

9. Section 311 of the penal code of Code of Government of Ceylon, legislative enactment, 1970.

10. Von Arx T, Filippi A, Lussi A. Comparison of a new dental trauma splint device (TTS) with three commonly used splinting techniques. Dental Traumatology 2001; 17(6): 266-74.

11. Olsburgh S, Jacoby T, Krejci I. Crown fractures in the permanent dentition: pulpal and restorative considerations. Dental Traumatology 2002; 18(3): 103-15.

12. Telfer MR, Jones GM, Shepherd JP. Trends in the aetiology of maxillofacial fractures in

the United Kingdom (1977-1987). British Journal of Oral Maxillofacial Surgery 1991; 29(4): 250-5.

13. Fasola AO, Nyako EA, Obiechina AE, Arotiba JT Trends in the characteristics of maxillofacial fractures in Nigeria. Journal of Oral Maxillofacial Surgery 2003; 61(10): 1140-3.

for medico-legal examination. Accidental and sports dental injuries are not reported to police as there are no medico-legal significance. Industrial and therapeutic dental injuries or dental malpractices were not reported in this study and it is something we need to make a note of.

Similar to a study done by Batista and others in 2012 (4), in this study too, RTT was the most common cause of oral and maxillofacial fractures/dislocations.

Intrusion beyond 6 mm cannot regenerate a functional periodontal ligament and are prone to root resorption and eventual extraction. In these situations the decision is either immediate extraction or repositioning with the understanding that it is inevitable that the tooth will eventually be extracted (7). When such extractions are done by the dental surgeon for traumatic subluxation, the injury is categorized as grievous by the forensic medical practitioner.

When root fractures are found in traumatic subluxation by the dental surgeon, the injury is categorized as grievous by the forensic medical practitioner (9).

Splinting is the standard of care for stabilization of replanted or repositioned permanent teeth following trauma (8). When such active dental therapy is used in traumatic subluxation, the injury is categorized as grievous hurt (9).

In this study, there were 43 victims with mobile (subluxation) teeth. The phenomenon of a 'mobile tooth' is a medico-legal challenge. In such instances, the dental surgeon's expert opinion is required to ascertain traumatic or natural subluxation. A traumatic subluxation is categorized as grievous hurt under section 311of the penal code of Sri Lanka (9) in following circumstances: (a) root fracture, (b) subluxation that warrants extraction of affected tooth/teeth, (c) active dental therapy such as wiring or plastering, (d) if mobility persists more than 20 days of the incident.

According to the above criteria there were 02 cases of subluxation due to root fracture, 02 cases of mobile tooth needing extraction and 04 cases that needed active dental therapy and those 08 cases were classified as grievous hurt without necessitating further review.

Fixation of a 'mobile tooth' depends on multiple reasons. Review is important to decide whether a mobile (subluxated) tooth has fixed or not after 20 days in order to categorize hurt. If traumatic subluxation persists for more than 20 days it is categorized as grievous hurt and if fixes within 20 days it is non-grievous hurt. Out of 43 mobile teeth, 14 cases were found 'mobile' even after 20 days by dental surgeon and were categorized as grievous hurt by the forensic medical practitioner (9). Four were found 'fixed' after 20 days by dental surgeon and were categorized as non-grievous hurt by forensic medical practitioner.

Seventeen victims out of 43 subluxated cases did not present for the 'review after 20 days' making them to be categorized as non-grievous by the forensic medical practitioner due to non-compliance. This is an important finding since this non-compliance by the patient may have been prevented or reduced by emphasizing the importance of presenting to 'review after 20 days' by the forensic expert examined and/or more so by the dental surgeon concerned.

Crown fractures are categorized as grievous hurt under the penal code of Sri Lanka (9). There were 78 (53%) victims with crown fractures and in the study of Olsburgh and others in 2002 too, the crown fractures accounted for the highest percentage of all traumatic injuries in the permanent dentition (10).

Avulsion or dislocation of teeth is also considered as grievous hurt. In this study, there were 12 (8%) dislocations. According to Kenny

and others in 2003, if replanted within 5 minutes of avulsion, there is a chance of regeneration of the periodontal ligament and normal function (7). However, according to Sri Lankan grievous hurt law, even complete recovery without any complication following dental treatment or cosmetic surgery does not prevent such injuries being classified as grievous hurt.

Maxillofacial fractures (n=04) were categorized as endangering life under the penal code since the force that gives rise to the maxillofacial fracture may have effects on consciousness such as concussion.

In this study, the 2 root fractures were confirmed by peri-apical X-rays by the dental surgeon. X-rays is an important method of documentation and peri-apical dental X-rays are taken to capture the tip of the root. In dental injuries, intra-oral X-rays such as peri-apical, bitewing, palatal and extra-oral X-rays such as orthopantogram are taken. The orthopantograms are medico-legally more useful not only that it shows a panoramic view of the entire dentition and other adjacent structures on a single film but also it carries an identification number and site, which are important for medico-legal purposes. In this study none of the intra-oral dental X-rays carried identification numbers making them not useful to prove authenticity in medico-legal proceedings.

Traumatized teeth present a clinical challenge with regard to their diagnosis. Recent developments in imaging systems have enabled clinicians to visualize structural changes effectively. Computed tomography (CT), magnetic resonance imaging (MRI) and cone beam computed tomography are among the most commonly used systems in some countries (11). Application of such investigations among the victims of this study was not reported.

In this study, it was found that RTT caused more severe injuries such as fractures/dislocations when compared to injuries due to assaults ($p<0.05$). This could have been due to higher force of impact in RTT when compared to assaults.

Further, it was revealed that among males, the chance of getting severe fractures/dislocations were more common when compared with females ($p<0.05$). This could have been due to presence of more males than females in RTT which would yield a higher force and resulting severe injuries.

In this study, it was revealed that the younger victims below 30 years suffered severe injuries such as dislocations/fractures of teeth compared the 30 years or more age group ($p<0.05$). This could have been due to presence of more victims below 30 years (63%, n=33) than 30 years or above (37%, n=19) in RTT which would yield a higher force and resulting severe injuries. Further, this may be due to lesser maturity and strength of young teeth.

In some countries, due to legislative changes and preventive measures involving the use of seat belts, air bags and driving under the influence of alcohol, the vehicle accidents resulting dental injuries have decreased, while interpersonal violence has emerged as the predominant cause (12,13). In Sri Lanka, though there are no special air bag laws, there are laws to regulate the use of seat belts and driving under the influence of alcohol. According to the Motor traffic act of Sri Lanka, 1990, driving after consumption of alcohol or drugs is banned. According to the Motor Traffic (Seat Belts) regulation gazette issued by Transport Ministry in 2011, it is mandatory wearing seat belts by every person travelling in the driving seat or the front passenger seat of motor vehicles specified in the gazette. In spite of the legislative changes in Sri Lanka, RTT turned out to be the predominant cause for dental injuries in this study, necessitating further research.

Conclusions

More severe dental fractures/dislocations were common among males, RTT victims, and persons below 30 years of age. In traumatic subluxations, dental experts should emphasis the importance of 'review medico-legal dental examination after 20 days' in order to enhance victim compliance and to achieve accurate categorization of hurt. Inclusion of an identification number especially in all medico-legal X-rays to ensure the authenticity is reiterated.

To minimize dental injuries, it is necessary to enforce existing laws related to motor traffic and criminal behaviours. Further, the development of evidence based preventive program and the development of evidence based medico-legal management guidelines for dental injuries are suggested.

Acknowledgment

Dr. DSK Karunanayake, Dr. ND Ruchira, Registrars Dr. HKR Sanjeewa, Postgraduate trainees and Dr. H Suffian at the Office of the Judicial Medical Officer, Teaching Hospital, Colombo South for collection of samples.

References

1. Glendor U. Epidemiology of traumatic dental injuries- a 12 year review of the literature. Dental Traumatology 2008; 24(6): 603-11.

2. Ugboko VI, Odusanya SA, Fagade OO Maxillofacial fractures in a semi-urban Nigerian teaching hospital. A review of 442 cases. International Journal of Oral and Maxillofacial Surgery 1998; 27(4): 286-9.

3. Ramli R, Rahman NA, Rahman RA, Hussaini HM, Hamid AL. A retrospective study of oral and maxillofacial injuries in Seremban Hospital, Malaysia. Dental Traumatology 2011; 27(2): 122-6.

4. Batista AM, Marques LS, Batista AE, Falci SG, Ramos-Jorge ML Urban-rural differences in oral and maxillofacial trauma. Brazilian Oral Reseach 2012; 26(2): 132-8.

5. Ekanayake L, Perera M. Pattern of traumatic dental injuries in children attending the University Dental Hospital, Sri Lanka. Dental Traumatology 2008; 24(4): 471-4.

6. Al Ahmed HE, Jaber MA, Abu Fanas SH, Karas M. The pattern of maxillofacial fractures in Sharjah, United Arab Emirates: a review of 230 cases. Oral Surgery, Oral Medicine, Oral Pathology, Oral Radiology and Endodontics 2004; 98(2): 166-70.

7. Kenny DJ, Barrett EJ, Casas MJ. Avulsions and intrusions: the controversial displacement injuries. Journal of Canadian Dental Association 2003 May; 69(5):308-13.

8. Andreasen FM, Andreasen JO, Bayer T. Prognosis of root-fractured permanent incisors--prediction of healing modalities. Endodontic Dental Traumatology 1989; 5(1): 11-22.

9. Section 311 of the penal code of Code of Government of Ceylon, legislative enactment, 1970.

10. Von Arx T, Filippi A, Lussi A. Comparison of a new dental trauma splint device (TTS) with three commonly used splinting techniques. Dental Traumatology 2001; 17(6): 266-74.

11. Olsburgh S, Jacoby T, Krejci I. Crown fractures in the permanent dentition: pulpal and restorative considerations. Dental Traumatology 2002; 18(3): 103-15.

12. Telfer MR, Jones GM, Shepherd JP. Trends in the aetiology of maxillofacial fractures in

the United Kingdom (1977-1987). British Journal of Oral Maxillofacial Surgery 1991; 29(4): 250-5.

13. Fasola AO, Nyako EA, Obiechina AE, Arotiba JT Trends in the characteristics of maxillofacial fractures in Nigeria. Journal of Oral Maxillofacial Surgery 2003; 61(10): 1140-3.

Case Report I

Sri Lanka Dental Journal 2013; 43(03) 126-130

Calcinosis cutis at multiple sites: A Diagnostic Challenge

Amit Aggarwal, Ravinder Singh, Deepak Gupta, Soheyl Sheikh, Shambulingappa Pallagati, Jyoti Mago

Abstract

Dystrophic calcification is deposition of calcium salt in degenerated tissues in the presence of normal calcium and phosphorous metabolism. It usually occurs in injured tissues. A case of a young man with isolated dystrophic calcifications at multiple sites in body is presented. The objective of this case study was to present an unusual case as the lesions were found in normal tissue and the diagnostic challenges it posed as there was no history of trauma. This is different from systemic mineral imbalance causing metastatic calcification and needs to be differentiated.

Keywords: dystrophic calcifications; supra-masseteric; multiple.

Introduction

Calcification is a process in which calcium salts build up in soft tissues, causing it to harden.[1] Calcifications of the soft tissue structures in the head and neck can occur either as physiological or pathological mineralization.[2] Pathological mineralization is more likely to occur in articular cartilage,vascular tissues, ligaments and glandular tissues and is usually associated with chronic inflammation or scarring.[2]

Calcinosis is an abnormal condition characterized by deposition of calcium in any part of body, tissue or skin. When this condition occurs in skin it is known as calcinosis cutis or cutaneous calcification. Intraoral mucosal calcified nodule is a recently recoganized entity of the oral cavity that represents the idiopathic form of calcinosis cutis.[3,4]

Calcinosis is reported in four main forms, namely dystrophic calcinosis, idiopathic calcinosis, metastatic calcinosis and iatrogenic calcinosis.[1] The other forms described

Dr. Amit Aggarwal MDS, Assistant Professor, Oral Medicine and Radiology, M.M. College of Dental Sciences and Research, Mullana, Ambala. E- mail: dramitagar1@yahoo.co.in

Dr. Ravinder Singh MDS, Assistant Professor, Oral Medicine and Radiology, M.M. College of Dental Sciences and Research, Mullana, Ambala. E-mail: drravindersohi@gmail.com

Dr. Deepak Gupta MDS, Assistant Professor, Oral Medicine and Radiology, M.M. College of Dental Sciences and Research, Mullana, Ambala. E-mail: drdeepak_26@gmail.com

Dr. Soheyl Sheikh MDS, Professor and Head, Oral Medicine and Radiology, M.M. College of Dental Sciences and Research, Mullana, Ambala. E-mail: soheyl@cliffhanger.com

Dr. Shambulingappa Pallagati MDS, Professor, Oral Medicine and Radiology, M.M. College of Dental Sciences and Research, Mullana, Ambala. E-mail: pallagatti@hotmail.com

Dr. Jyoti Mago Post graduate student, Department of oral medicine and radiology, M.M. College of Dental Sciences and Research, Mullana, Ambala, Haryana (India) Pin 133203 Tel: +91 9729421685 (Mobile) E-mail: jyotimago22@gmail.com

are calcinosis universalis and calcinosis circumscripta.[5] In calcinosis circumscripta there is localized collection of calcium in skin and subcutaneous tissue, usually around joints, whereas in calcinosis universalis the calcium is deposited diffusely in skin, subcutaneous tissue and muscles.

Dystrophic calcification is a term that describes the deposition of calcium in abnormal tissue as in hyalinized scars, degenerated foci in leiomyomas, caseous nodules, etc.[6] This entity is noted most frequently in damaged or devitalized subcutaneous tissues, secondary to trauma or infection, and is also described in connective tissue diseases.[6]

The term metastatic calcification is used when a systemic mineral imbalance would elevate calcium levels in blood and all tissues. Mineralization of soft tissues can occur in hyperparathyroidism, hyperadrenocorticism, vitamin D toxicity, and hypervitaminosis.[7]

Dystrophic calcification at multiple sites is rare, its pre-operative diagnosis posing a challenge in view of differential diagnosis.

The aim of this article is to report a case of such rare entity in the facial area.

Case Report

A 25-year-old man reported to the department of oral medicine and radiology, Dental College, MM University, with a complaint of multiple painless swellings over the left masseteric region and in front of auricle since 2 months. Patient had a history of pulmonary tuberculosis which was diagnosed 10 years back for which he took antitubercular regimen. Patient did not report any incidence of trauma to the affected site.

On examination, multiple small swellings were present over left masseteric region and in front of auricle of about 1mmx1mm in size with the same color as that of surrounding skin. Palpation revealed the presence of firm, non-tender, well-circumscribed multiple mobile masses, covered by normal skin and apparently not attached to the underlying structures. The masses became more pronounced while the patient opened his mouth or masseter muscle was contracted (fig. 1).

Figure 1. Multiple spherical masses become evident when masseter muscle was contracted.

On further examination of the whole body, similar small swellings were present on the left thigh region which was also firm. Routine blood investigations were within normal range. The patient's serum calcium, phosphate, uric acid, alkaline phosphatase, creatinine and blood urea nitrogen levels were within normal limits.

The preoperative clinical impression was that the lesions represented a benign osseous process, possibly myositis ossificans or osseous choristomas or as calcified lymph nodes secondary to tuberculosis.

Panoramic radiograph revealed multiple irregular calcified structures on left side over ramus of mandible (fig 2). Ultrasonography revealed multiple calcified masses in left masseteric soft tissue and on left thigh along with small collection of pus in the subcutaneous tissue. Three-D reconstruction and axial CT Scan revealed cluster of densely calcified aggregates in subcutaneous tissues in left infra-temporal

region (fig 3, 4) which were further excised (fig 5).

Figure 2. Panoramic radiograph showing multiple irregular calcified structures on left side over ramus of mandible.

Figure 3. Three-D Reconstruction shows multiple calcified structures over left ramus of mandible without involving the bony structures.

The incisional biopsy was done under local anesthesia and the specimens were sent for microscopic examination. Pathologic examination showed well-circumscribed dystrophic calcific deposits with fibrous connective tissue (fig.6). The lesion was then fully excised and this excisional biopsy also revealed dystrophic calcific deposits with fibrous connective tissue. Therefore histopathological diagnosis of dystrophic calcification was given.

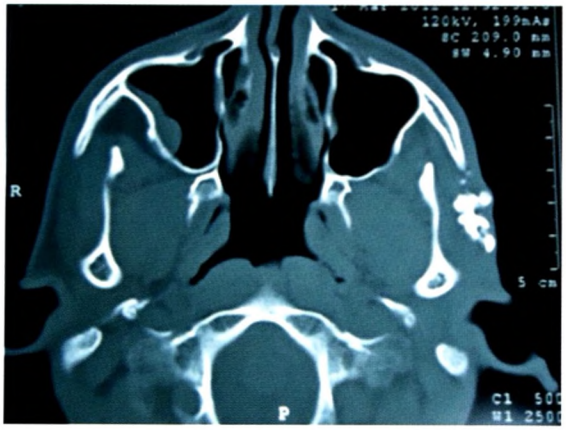

Figure 4. Axial view of CT scan examination revealed multiple hyperdense masses

Figure 5. Excised calcified nodule

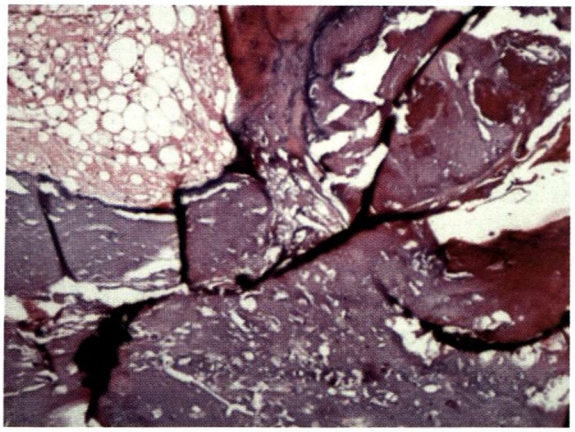

Figure 6. Irregular and haphazard areas of calcification with varying degree of mineralization within dense fibrous connective tissue stroma.

Owing to its presence on skin, final diagnosis of calcinosis cutis was given.

Discussion

Calcification of the soft tissues may represent a nonspecific local response or be a manifestation of a complex underlying disease.[6] A generally accepted classification of calcification is not to be found in the literature. According to Boulman *et al*, soft tissue calcification can be classified into five similar categories: metastatic calcification, tumoral calcification, idiopathic calcification, calciphylaxis, and dystrophic calcification.[6]

Dystrophic calcification, which includes calcinosis, occurs in healthy persons with normal metabolism and in degenerating and devitalized tissues. It is noted most often in subcutaneous tissues secondary to trauma or infection and is also described in systemic lupus erythematosus, scleroderma, or dermatomyositis. Injured tissue of any kind has been suggested to be predisposed to dystrophic calcification.[8]

When soft tissue is adjacent to bone, it is sometimes difficult to determine whether the calcification is within bone or soft tissue. Differential diagnosis includes calcification of lymph nodes, parotid salivary gland calcifications, sialolithiasis in parotid duct/ gland, calcification of carotid artery. Other rare differential diagnosis includes pilomatrixoma, choristoma and foreign body granuloma.

In the case presented, medical history revealed tuberculosis which indicated a possibility of calcified lymph nodes in infra-temporal area but radiological examination countered it. No history of trauma was established. This case also coincides with the study of Martin[6], who hypothesized that dystrophic calcification is attributed to stress in the region of tendinous insertion of the masseter muscle. No possible cause for the dystrophic calcifications was elicited. Such cases should be studied in detail for any underlying pathology. Owing to its presence on skin, diagnosis of calcinosis cutis was given.

Surgical ablation of the dystrophic calcification is the optimal treatment as is done in our case. Carbon dioxide laser therapy is an additional treatment option for smaller and superficial lesions.

Conclusion

This article briefly highlights a case of dystrophic calcification and draws attention to the differential diagnosis of the condition and its management. The lack of a classification system of soft tissue calcifications complicates the management.

References

1. Mohiuddin S, Badal S, Doiphode A, Sultana S. Multiple supramasserteric dystrophic calcinosis. Annals of Maxillofacial Surgery 2012;2(1):74-76.

2. Scarfe W C, Farman A G. Soft Tissue Calcifications in the Neck: Maxillofacial CBCT Presentation and Significance. From the Spring 2010 AADMRT Newsletter.

3. El-Mofty SK, Santa Cruz D. Mucosal calcified nodule. The oral counterpart of subepidermal calcified nodule. Oral Surg Oral Med Oral Pathol 1992; 73:472-5.

4. Demsar WJ, Williams SB. Palatal mucosal calcified nodule: case report and review of literature. Essay Program #27.Proceedings from the American Academy of Oral and Maxillofacial Pathology Annual Meeting. New Orleans, LA. April 2002.

5. Sivapathasundaram B, Rajendran R, Oral Aspects of Metabolic diseases; In Sivapathasundaram B, Rajendran R; editors Shafer's Textbook of Oral Pathology;6th ed. Elsevier; Noida; 2009;p.615.

6. Sencimen M, Gulses A, Ogretir O, Gunhan O, Ozkaynak O, Okcu K M. Dystrophic calcifications arising in the masseter muscle: A case report. Quintessence Int 2010;41:295–297.

7. Naik CS, Arya AA, Deshmukh SD, Gaopande V. A unique case of dystrophic calcification in masseter: A diagnostic challenge. Indian J Otolaryngol Head Neck Surg December 2011. [online ISSN-0973-7707]

8. Chen WS, Eng H L. Tumoral calcinosis after thumb tip injury: Case report. J Trauma 1995;38:952-4 .

Case Report II

Sri Lanka Dental Journal 2013; 43(03) 131-134

Primary oral myiasis: A case report

Muhammad Zeeshan Baig, Muhammad Junaid, Quratulain Qadir, Syed Gulzar Ali Bukhari

Introduction

Myiasis is the infestation of live human and vertebrate animal with dipterous larvae which feed on the host's dead or living tissue.In some animals, larvae of the flies of the family can, for example,produce gingival and lingual infections in horses.Scott, who presented 120 human cases in North America between 1952 and 1962, reported the first case of myiasis in a human oral cavity in 1964 which was the only case (0.9%) of oral myiasis in the series. Oral myiasis affecting the oral cavity is rare and is mostly caused by fly larvae which belong to the and families. Although all age groups may be affected, the damage caused to infants is more severe and may be fatal.This type of infection occurs mainly in tropical areas and is associated with inadequate public and personal hygiene. Adult flies are strongly attracted to putrefactive odors and usually lay eggs on necrotic areas in wounds, blood or natural openings where they hatch and transform into larvae which feed on the host's dead or living tissue, liquid body substance or ingested food. This case report is about five cases reported to Armed Forces Institute of Dentistry Rawalpindi in the year 2011. only two of them will be presented here.

Patient - 1

A 12-year-old mentally handicapped boy was referred to AFID from CMH Muzafarabad, parents had seen larvae in their son's mouth two days before. He had had a dental extraction five days previously, and the lesion had been attacked by the fly. On examination, some subcutaneous larvae were seen in the dental alveolus, and it was diagnosed as a case of oral myiasis Mechanical debridement was done in Local anesthesia. Larvea were counted and collected in saline length of larvae was also noted area irrigate with sodium hypochlorite patient was admitted at MH child surgical and was monitored IV line for fluids was maintained and his mouth was covered with net to keep flies away from reaching moist humid oral cavity.with consult to pediatrition Ivermectin 6mg tablets were used. As we had difficulty in arranging IV ivermectin Twenty-four hours after the first dose, another 6mg was given. Forty-eight hours after the first dose, some larvae still persisted in the site, so he was operated under general anaesthesia, to remove the larvae and debride the wound. A full thickness flap was raised and all visible larvae removed from palatal area. The wound was irrigated liberally

Dr. Muhammad Zeeshan Baig (Correspondence) — Senior Registrar, Oral & Maxillofacial Surgery Department Rawal Institute of Health Sciences, Islamabad. House 426, Street 36, Sector I-8-2 Islamabad. Tel: 00 92 321 4669917 E-mail: zeesh7@hotmail.com

Dr. Muhammad Junaid — Resident, Oral surgery department Armed Forces Institute of Dentistry, Rawalpindi

Dr. Quratulain Qadir — Resident, Oral surgery department Armed Forces Institute of Dentistry, Rawalpindi

Dr. Syed Gulzar Ali Bukhari — Classified Facio Maxillary Surgeon, Armed Forces Institute of Dentistry, Rawalpindi

with saline, debrided, and the wound closed with 4/0 polyglactin 910 (Vicryl®). After that augmentin1.2 g 6-hourly and metronidazole 500 mg 8 hourly were given. This was continued for five days postoperatively, and chlorhexidine 0.12%. was used for local cleansing. After seven days of treatment, the wound had healed completely. Twenty-four larvae were removed.

Patient - 2

A 70-year-old female mentally handicapped patient local resident of Rawalpindi who weighed 65 kg presented to AFID with lesions in palate with infestation of larvae. (Figure 1)

On examination we noted that the patient was senile, and dependent on relatives to help with her general boy & oral hygiene.She constantly opened her mouth, and had ulcerated palatal lesions and some submucosal larvae. (Fig. 2).

After blood count, white cell count, and tests of renal and hepatic function, other conditions could be excluded. Ivermectin 12-200 µg/kg was prescribed orally, together with intravenous rehydration with 0.9% physiological saline and augmentin 1.2 g every 6 hours.

Figure 1. 70 year old female patient

The following day some larvae still remained. However, the patient's relatives reported that several other dead larvae were visible on the wound. Relatives had to provide care to prevent the patient from swallowing or aspirating larvae so another dose of ivermectin 6mg - 100 µg/kg was given together with the supporting treatment. After 48 hours all larvae had disappeared, but the patient's relatives reported that dead larvae were being discharged from the lesion. (Figure 2)

Figure 2. Dead larvae discharged from the palatial lesion in patient - 2

Discussion

Risk factors among the development of oral myiasis are supparative lesions facial trauma and poor oral hygiene .oral cavity humid environment always favours flies to lay egg. Proper diagnosis of Primary Oral myiasis needs clinical evaluation and visualization of larvae (maggets). Entomological identification is necessary to plan proper treatment. 2 However, due to lack of facilitation professionals hardly ever send the larvae to special laboratories to be investigated as we were not able to do it in our one case.2. Several substances have been used to try to kill subcutaneous larvae and treat the lesions, among which are: chloroform, ether, camphor, and alcoholic solution in association with tobacco, sodium hypochlorite, and so on. However, none of them gave particularly good results. There are many options for treating the lesion, but the simplest is the mechanical removal of the larvae with tweezers, usually under local anesthesia (or even general).[2-4] If clinicians are unable to remove the larvae completely, the remaining larvae can cause

inflammatory reactions, infections, or even granulomas. Larvae can also be removed bydebridment[2,5,6] Nowadays, successful cases of treatment with ivermectin have been described. its easily available in Pakistan & has been declared safe for human use[1,7] After they had treated seven patients with ivermectin, some authors concluded that the initial dose of 200μg/kg would not always be able to eliminate all subcutaneous larvae,so they required a further dose of 100μg/kg 24 hours later. Some authors have suggested that the treatment should start with doses of up to 300μg/kg; that is, for patients from 40 to 60 kg–2 tablets (12 mg) are indicated, and 3 tablets (18 mg) should be used for patients weighing from 60 to 90 kg. Shinohara *et al.*[1] reported a moderate success when treating oral myiasis with ivermectin 6mg given orally, and repeated after 24 hours. However, they did not mention the patient's weight so readers were not able to relate the patient's weight to the amount of drug to be given in future investigations.

It seems that the dose of ivermectin was about 200μg/kg, as the same author emphasised that dose in another paper.[1] But on other hand an other author treated a patient with oral myiasis and pointed out that even after five days using ivermectin 6mg the larvae remained alive. An operation was therefore necessary to remove the larvae completely. Unfortunately, in that paper the patient's weight was not quoted either, but the failure of treatment was certainly caused by the use of too small a dose or the failure to continue the drug on subsequent days, which is necessary. In case 1 we failed to eliminate the larvae, probably because the dose was too small, even though there was a correct replication during the following days. therapeutic plans should be made it is highly recommended. We adopted this plan in case 2, in whom ivermectin 200-300μg/kg was given with a repeat dose of 100μg/kg the following day, which made the treatment highly effective. Some authors have argued that ivermectin may not be effective in cases of local myiasis with cloistered larvae, so the larvae should be killed subcutaneously without being removed. This statement does not seem to correspond to reality as, according to arguments,[7] the larvae die and are eliminated spontaneously simply by washing of the site,either with physiological saline or with antiseptic solution,as shown in case 2. One of the main advantages of ivermectin is that it is not necessary to operate on the patient to remove the larvae. It is important to prescribe antibiotic treatment to avoid secondary infection.[3,7]

All our patients were medically compromised and reported to AFID along with relatives who were responsible for their personal and oral hygiene and patients were neglected simple method in treatment can b just give patient ivermectin and instruct attendents to cover mouth with a thin clothes to keep house flies away specially after eating food and if patient had any oral surgery done.

References

1. Shinohara EH. Treatment of oral myiasis with ivermectin. Br J Oral Maxillofac Surg 2003;41:421.

2. Ng KHL,YipKT, Choi CH, et al.Acase of oral myiasis due to Chrysomya bezziana. Hong Kong Med J 2003;9:454-6.

3. Baliga MJ, Davis P, Ra'ı P, Rajasekhar V. Orbital myiasis: a case report. Int J Oral Maxillofac Surg 2001;30:83-4.

4. Gomez RS, Perdig˜ao PF, Pimenta FJ, et al. Oral myiasis by screwworm Cochliomyia hominivorax. Br J Oral Maxillofac Surg 2003;41:115-6.

5. Aguiar AMM, Enwonwu CO, Pires FR. Noma (cancrum oris) associated with oral myiasis in an adult. Oral Dis 2003;9:158-9.

6. Gursel M, Aldemir OS, Ozgur Z, Ataoglu T. A rare case of gingival myiasis caused by d'ıptera (Calliphoridae). J Clin Periodontol 2002;29:777-80.

7. Shinohara EH, Martini MZ, Oliveira Neto HG, Takahashi A. Oral myiasis treated with ivermectin: case report. Braz Dent J 2004;15:79-81.

Instructions to Authors

The Sri Lanka Dental Journal publishes the following categories of articles which have relevance to Dentistry and allied sciences.

1. Leading articles - One article per issue. It may be solicited by the Editor. Authors are welcome to submit leading articles on current topics of interest. One's expertise or commentaries on general practice etc. They should be approximately 1500 words in length. References should be 20 or less.

2.Reviews - Reviews are detailed surveys of published research pertinent to dentistry and associated sciences. They should be critical in nature and should not normally exceed 3000 words and 30 references.

3. Research articles - Articles resulting from research work belong to this group. Results from routine clinical examinations or laboratory investigations will not be considered under this category. Subjects may vary from clinical trials to basic science research, historical analysis to dental economics. They should not exceed 3000 words and 30 references. A reasonable number of tables and illustrations will be accepted.

4. Short reports - These include reports on current topics, modified techniques. new materials, practice management etc. Interesting results from routine, clinical work or laboratory ill vestigations also may be accepted.

5. Case reports - Reports such as of rare diseases or conditions. Modifications to accepted treatment procedures, new management methods etc. may be included in this category.

6. Letters to Editors - Subjects unlimited, but may include short critique of published papers in the SLDJ.

7. Miscellaneous topics - Subjects unlimited and the format are free. These may also include details of scientific meetings, conferences, annual sessions, examinations, news and views, visits and obituaries.

8. Proceedings of annual sessions - Abstracts from annual sessions of the SLDA and other colleges will be published under this category.

Submission of manuscripts

Authors submitting a paper do so on the Understanding that no part has been published before. that it is not being considered for publication elsewhere and that it has been read and approved by all the authors.

Manuscripts including Tables and Figures should be sent in triplicate as the work will be reviewed by two or more referees. While papers are subject to editing. The journal does not hold it responsible for statements made by the contributor. The author alone is responsible for the statements made in his paper.

Submission of a manuscript means that authors automatically agree to assign exclusive copyright to the Sri Lanka Dental Association if and when the manuscript is accepted for publication.

Manuscript on disk

Once an article has been accepted for publication. the author will be asked to supply a copy of the final manuscript on disk together with two copies of the complete manuscript. Every disk must be clearly labelled with the name of the author, title, software and program version number.

Manuscript style

The manuscripts should be typed, double-spaced: on A4 (2 I 2x297 mm) paper and submitted in correct English: both English and American spelling are acceptable, provided this is consistent throughout the manuscript.. Manuscripts not submitted in proper format or in poor English may be returned without review. The format of a manuscript should be as

follows: Title page. Abstract. Introduction, Material and methods. Results. Discussion. Acknowledgements. References. Figure legends. and Tables, arranged in that order.

Title page - The title page should contain the following information in the order given: 1) a concise but informative title; 2) author's full names' (without degrees and titles): 3) author's institutional affiliations: 4) a running title. not exceeding 40 letters and spaces; 5) name, address, telephone, telefax and electronic mail address of the author responsible for correspondence.

Abstract page - Original and review articles must contain an abstract of approximately 250 words with four specified subtitles:

I) Objective: An introductory sentence indicating the objective and purpose of the study.

2) Material and methods: A description of experimental procedure including applicable statistical evaluation.

3) Results: A summary of the new. Previous unpublished data and results.

4) Conclusion: A statement of the study's conclusion 3-5 key words according to Index Medicus should be provided.

Introduction - The introduction should carry sufficient background information on the subject of study.

Material and methods - Procedures should be described in such detail as to make it possible to repeat the work. Subheadings may be used to improve clearness. Correct unit abbreviations should be used (e.g.; "h", "min", "s" and "Fm" rather than "hr", "minutes", "sec" and "Fl". respectively).

The authors should consider the ethical aspects of their research and ensure that the work has been approved by an appropriate Ethical Committee. Where applicable, a copy of the ethical clearance certificate should be attached. In human experimentation. informed consent from individuals should be Obtained and this should preferably be stated.

Statistical analysis - Since many scientific investigations rely on statistical treatment, authors are strongly urged to consult a person with in-depth statistical knowledge. Manuscripts with a clear element of statistics are regularly refereed by the Journal's statistics consultant.

Results - The Results section should clearly and concisely present the findings of the research, as a rule in the past tense without subjective comments and reference to previous literature. The results should be supported by statistical or illustrative validation. For the sake of clarity this section may have subheadings.

Discussion - This section should present the interpretations of the findings and is the only proper section for subjective comments. Authors are strongly urged to avoid undue repetition of what has been reported in Results.

Tables - The tables should be numbered in the order" of appearance in Arabic numerals, Each table should have a brief explanatory title. Each table; should be typed on a separate sheet, with due regard to the proportion of the printed column/page.

Figures - All graphs, drawings, and photographs are considered figures and should be numbered in the order of appearance in Arabic numerals. Each figure should have a brief and specific legend, and all legends should be typed together on a separate sheet of paper. Photographs should be glossy prints and the reverse should give the figure number, title of paper principal author's name and have a mark indicating the top. Colour illustrations may be submitted in instances where their use may contribute significantly to the scientific value of the article. Colour illustrations may be printed free of charge at the Editor's discretion, whereas others may be printed at the author's expense.

References - References are listed double-spaced in a separate reference section immediately following the text. References are numbered consecutively in the order in which they appear in the text; do not, alphabetise. Identify references in texts, tables and legends by Arabic numerals (within parenthesis).

Congress abstracts should not be used as references nor may "unpublished observations" and "personal communications" be placed in the reference list. References cited as "in press" must have been accepted for publication and not merely in preparation or submitted for publication

Examples of correct. forms of references are given below. These are based on the format used in the *Index Medicus.* Abbreviate journal names according to the *List of Journals Indexed,* printed annually in the January issue of *Index Medicus.* List all authors; do not use *et al.* in the reference list.

Journals

Standard journal article

Bartlett IG, O'Keefe P. The bacteriology of the perimandibular space infections. JOral Surg 1979; 37: 407409.

Corporate (collective) author

WHO COLLABORATING CENTRE FOR ORAL PRECANCEROUS LESIONS. Definition of leukoplakia and related lesions: an aid to studies on oral precancer. Oral Surg Oral Med Oral Pathol 1978; 46: 518-539.

Unpublished article

Barker DS. Lucas RB. Localised fibrous growth of the oral mucosa. J Dent Res 1965: in press.

Books and other monographs

Pindborg JJ Atlas of diseases of the oral mucosa. 5th edition.. Copenhagen: Munksgaard, 1992: 50-66.

Chapter in book

Boyde A. Amelogenesis and the structure of enamel. In: Cohen B. Kramer KH (eds). Scientific Foundations of Dentistry. William Heinemann Medical Books Ltd. London. 1976: 335-352.

No authror given

International statistical classification of diseases and related health problems, 10th revision, vol 1. Geneva: World Health Organisation, 1992; 550--564

DENTA®

ADULT TOOTHBRUSH

SLS 276

SLDA ACCEPTED SRI LANKA DENTAL ASSOCIATION

DENSU Laboratory Service

DENSU

DENTAL LABORATORY

Specialists for all dental laboratory works

* Crown and Bridge - PFM with VITA VMK Master Classic shades & 3D shades
* Implant Crown & Bridge - PFM with VITA VMK Master Classic shades & 3D shades
* Milling Crowns & Attachments,
* Mouth Guard, Retainer Bleaching Tray
* Gold & Metal Crowns
* Chrome - Cobalt Dentures - Special Germany BEGO Metal Nickle Free
* Flexible Dentures
* Prosthetics & Orthodontics

All Ceramic Systems

* CAD/CAM - Zirconia Crown & Bridg with VITA VM9 3D shades.
* VITA In Ceram - Alumina with VITA VM7 3D Shades Porcelain Materials Crowns.
* VITA Press Ceramic Systems - With VITA PM9 Crowns, Veneers, Inlay & Onlays.
* CAD/CAM Crown & Bridg - PFM with VITA VMK classic shades & 3D shades.

Dental Laboratory Equipments & Meterials Available

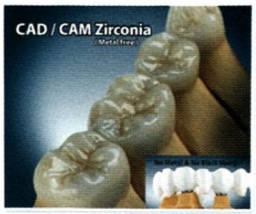

Renfert Whip Mix VITA BEGO valplast Flexible Partials

No. 08 Norris Cannel Road, Colombo - 10, Sri Lanka.

Tel : +94 11 268 0336, 11 268 0337 Fax : +94 11 268 0338

Hot Line : +94 77 767 8116, +94 72 223 8121

email: densudentallab@sltnet.lk Web : www.densu.lk

Rapidene™

Paracetamol 500mg & Codeine Phosphate 8mg

Because FASTER Action Causes RAPID RELIEF...

- Painful Mouth Ulcers,
- Denture Irritation,
- Cold Sores,

are some common problems faced by the community.

Oraleez gel™

Choline salicylate 8.714% w/w, cetalkonium chloride 0.010% w/w.

Fast acting gel for mouth ulcers

SUGAR FREE

Brings your smile back, FASTER

TRIPLE ACTION CONTROL

Manufactured & Marketed by

Astron
Since 1956

Astron Limited, 688, Galle Road, Ratmalana, Sri Lanka.
Tel : +94 11 2636741, 5566741 Fax : +94 11 2636173
E-mail : astron@astron.lk Web : www.astron.lk

www.ideabase.us

Signal

SUPERIOR CAVITY PROTECTION*

NON-FLUORIDE TOOTHPASTE

Vs

Signal STRONG TEETH
Calcium+Fluoride for Superior Cavity Protection

WITH CAVITY PROTECTION SHIELD

NEW

Signal STRONG TEETH
Calcium+Fluoride for Superior Cavity Protection

Rs. 40/- upwards

0112 629 629
Call us

Unilever

*Based on maximum permissible level of fluoride as anticavity agent in chalk based toothpaste formulation.
Creative visualization of protection against cavities offered by fluoridated toothpaste Vs non fluoridated toothpaste without actives.